

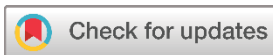## Systematic Review

# Presentation and Management of Thyroid Hydatid Cyst: A Comprehensive Systematic Review of the Literature

Abdullah A. Qadir<sup>1</sup>, Ismael Y. Abdullah<sup>2</sup>, Muhammed Bag A. Ali<sup>3</sup>, Rebaz O. Mohammed<sup>4</sup>, Hardi M. dhair<sup>4</sup>, Yadgar A. Saeed<sup>4</sup>, Aso S. Muhialdeen<sup>4\*</sup>, Honar Othman Kareem<sup>4</sup>, Aras J. Qaradakh<sup>5</sup>, Sasan M. Ahmed<sup>4</sup>, Shaho F. Ahmed<sup>4</sup>, Hiwa O. Baba<sup>4</sup>, Ari M. Abdullah<sup>6</sup>, Abdulwahid M. Salih<sup>1</sup>, Fahmi H. Kakamad<sup>1</sup>, Berun A. Abdalla<sup>7</sup>

1. College of Medicine, University of Sulaimani, Madam Mitterrand Street, Sulaymaniyah, Kurdistan, Iraq
2. Kalar General Hospital, Sulaymaniyah, Kurdistan, Iraq
3. Smart Health Tower/Raparin, Karux Street, Rania, Sulaymaniyah, Kurdistan, Iraq
4. Smart Health Tower, Madam Mitterrand Street, Sulaymaniyah, Kurdistan, Iraq
5. Department of Radiology, Shorsh Teaching Hospital, Sulaymaniyah, Kurdistan, Iraq
6. Department of Pathology, Sulaymaniyah Teaching Hospital, Sulaymaniyah, Kurdistan, Iraq
7. Department of Biology, College of Education, University of Sulaimani, Madam Mitterrand Street, Sulaymaniyah, Kurdistan, Iraq

\* **Corresponding author:** [drasosaeed@gmail.com](mailto:drasosaeed@gmail.com) (A.S. Muhialdeen). Kaziway 1, House number 306/7, Zip code: 46001, Sulaymaniyah, Iraq



**Keywords:**  
Hydatidosis  
Echinococcosis  
Zoonosis  
Disease  
Hydatid Cyst

Received: February 5, 2024  
Revised: February 25, 2024  
Accepted: March 3, 2024  
First Published: March 10, 2024

Copyright: © 2024 Qadir et al. This is an open access article distributed under the terms of the Creative Commons Attribution License (<https://creativecommons.org/licenses/by/4.0/>), which permits unrestricted use, distribution, and reproduction in any medium, provided the original author and source are credited.

Citation: Qadir AA, Abdullah IY, Ali MBA, Abdulla SH, Mohammed RO, Dhahir HM, Saeed YA et al. Presentation and Management of Thyroid Hydatid Cyst: A Comprehensive Systematic Review of the Literature. Barw Medical Journal. 2024;2(2):56-62. <https://doi.org/10.58742/mp68zz49>

## Abstract

### Introduction

Hydatid cysts of the thyroid gland, though rare, pose a diagnostic and therapeutic challenge. This systematic review summarizes current knowledge on the presentation, diagnosis, and management.

### Methods

A systematic review of the published studies of thyroid hydatid cysts was conducted. The included studies of thyroid hydatid cysts had the following properties: 1) The thyroid infection was confirmed by diagnostic modalities, surgical findings, or histopathology. 2) The case presentation was provided in the study. 3) The cyst(s) were originally located or adhered to the thyroid and did not rupture into it from the other adjacent structures or organs.

### Results

Overall, 39 studies were compatible with the inclusion criteria. Turkey had the highest case occurrence (36%). Female predominance (59%) and a mean age of 38.33 years were observed. Mass (79.5%) was the most common symptom, followed by hoarseness of voice (4%). Serology (18.75% positive) and ultrasound (77.5%) were primarily used for diagnosis. Surgery was the mainstay of treatment (96%), with total thyroidectomy (32.6%) and left hemithyroidectomy (16%) being the most common approaches. No recurrence was reported in the follow-up period (0%).

### Conclusion

This review highlights the rarity, clinical presentation, diagnosis, and successful surgical management of thyroid hydatid cysts. Further research is needed to optimize diagnostic methods and explore alternative treatment options.

## 1. Introduction

Hydatid cyst, also known as hydatidosis or cystic echinococcosis, is a serious parasitic disease of humans caused by the larvae of the tapeworm *Echinococcus granulosus* [1]. The two predominant species responsible for human infection are *Echinococcus multilocularis*, inducing alveolar echinococcosis, and *Echinococcus granulosus*, the causative agent of cystic echinococcosis [2]. Notably, cystic echinococcosis is responsible for 95% of human echinococcal infections [3]. Humans are often the parasite's intermediate host; humans can become infected by eating contaminated food or water contaminated with the parasite's eggs or by coming into direct contact with the primitive hosts (sheep, goats, cattle, dogs, and other canines) [4]. It is endemic in a variety of geographical regions, including the Middle East, the Mediterranean, America, South Africa, and Australia [5]. The liver (65%) and the lungs (25%) are the two most frequently affected organs in humans. The hydatid cyst rarely affects the thyroid gland, even in endemic countries [3]. The thyroid gland may be affected by hydatid cyst illness, either primary (affecting the thyroid gland solely) or secondary (including numerous organs). Due to its rarity, echinococcosis is frequently misdiagnosed in unusual locations, such as the thyroid [6]. For echinococcosis in rare locations, including thyroid cystic echinococcosis, various countries and regions have implemented different treatment modalities, such as total thyroidectomy, partial thyroidectomy, and fine needle aspiration cytology (FNAC) [7].

This study aims to fill this gap by providing a systematic review of all reported studies concerning thyroid hydatid disease [1, 3, 4, 6, 7, 9–39].

## 2. Methods

### 2.1. Study design

The current systematic review followed the Preferred Reporting Items for Systematic Reviews and Meta-Analyses (PRISMA) guidelines.

### 2.2. Data sources and search strategy

Up to February 1, 2024, the Web of Science databases with Google Scholar were searched for papers describing hydatid cysts of thyroid glands. The search terms were thyroid hydatidosis, echinococcosis, zoonosis, thyroid disease, and hydatid cyst. References cited in the included studies were used to complement the data collection.

### 2.3. Eligibility criteria

The inclusion criteria for this study focused on case-report studies that described thyroid hydatid cysts. Excluded studies are those that were not peer-reviewed and were published in predatory journals [8].

### 2.4. Study selection

All studies have been found using electronic and manual searches, and all duplicates have been deleted. Two of the authors independently assessed the titles and abstracts of the

publications and excluded those that were irrelevant. Following the first screening, the same two authors assessed the full texts of the remaining publications based on the inclusion and exclusion criteria.

### 2.5. Data item

Microsoft Office Excel was used to extract the data. Each study yielded the following information, which was gathered by two authors: (1) basic information about the articles, such as title, first author's name, publication date, study design, and country; (2) characteristics of the presented cases, such as the number of reported cases, age, gender, past medical history, and past surgical history; (3) presenting symptoms, such as mass; (4) FNAC and hydatid cyst heama-glutenin. Other authors rechecked all the extracted data.

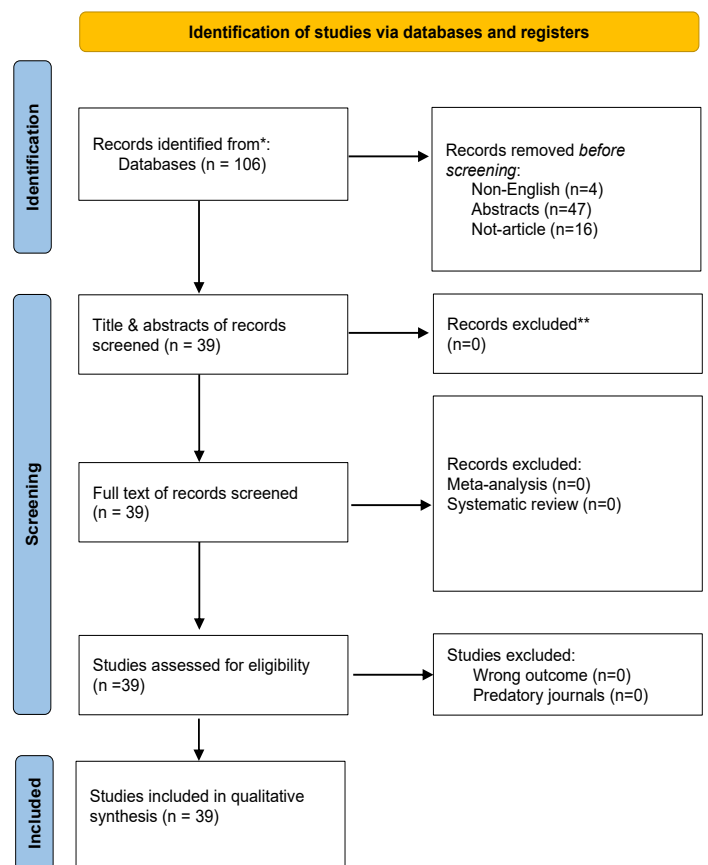


Figure 1. Study selection PRISMA flow chart.

## 3. Results

In total, 106 studies were obtained from the resources. Of these, 69 studies were promptly excluded during initial screening due to factors such as non-English language, abstracts, and absence of articles. Subsequently, the remaining 39 students underwent full-text screening, and all were determined to be eligible for inclusion as outlined in the predefined criteria (Figure 1). Therefore, no studies were excluded at this stage of the review process. Most of the cases (36%) were reported in Turkey, followed by Iran (10.2%) (Table 1) (Table 2). There was a

**Table 1:** The characteristics of the included studies.

First Author	Study design	No. of included case(s)	Country	Age	Gender	Reference
Sultana et al.	Case report	1	Pakistan	35	Female	[1]
Safarpour et al.	Case report	2	Iran	35, 50	Female, Female	[2]
Eshraghi et al.	Case report	1	Iran	34	Female	[3]
Akbulut et al.	Case report	2	Turkey	26,57	Female, Female	[4]
Jiang et al.	Case report	1	China	54	Male	[5]
Cossu et al.	Case report	1	Italy	54	Female	[6]
Sathekge et al.	Case report	1	south Africa	29	Female	[7]
Valverde et al.	Case report	2	Spain	66,5	Male, Male	[8]
Lada et al.	Case report	1	France	28	Male	[9]
Rauhofer et al.	Case report	1	Austria	14	Female	[10]
Cretu et al.	Case report	1	Romania	23	Female	[11]
Sersar et al.	Case report	1	Saudi Arabia	48	Female	[12]
ZULFIKAROGLU et al.	Case report	1	Turkey	50	Female	[13]
Erkilic et al.	Case report	1	Turkey	9	Male	[14]
ÇAPOĞLU et al.	Case report	1	Turkey	49	Female	[15]
Ozaydin et al.	Case report	1	Turkey	25	Male	[16]
Gökçe et al.	Case report	1	Turkey	33	Male	[17]
Chawil et al.	Case report	1	Libyan	12	Male	[18]
Jain et al.	Case report	1	India	55	Male	[19]
Abdwlwahid et al.	Case report	1	Kurdistan	48	Female	[20]
Hoysal et al.	Case report	1	India	14	Female	[21]
Azendour et al.	Case report	1	Morocco	23	Female	[22]
Rajabian et al.	Case report	3	Iran	16,24,60	Female, Female, Female	[23]
Yesim Erbil et al.	Case report	2	Turkey	21,70	Male, Female	[24]
Bouomrani et al.	Case report	1	Tunisia	8	N/A	[25]
Bousaadani et al.	Case report	1	NA	35	Male	[26]
Yalmaz et al.	Case report	3	Turkey	18,25,21	male, Female, male	[27]
Ekin et al.	Case report	1	Turkey	65	Female	[28]
Söğütü et al.	Case report	1	Turkey	18	Male	[29]
hassan bastanhigh et al.	Case report	3	Iran	16,24,60	Pregnant, Female, Female	[30]
Danila et al.	Case report	1	Romania	26	Female	[31]
saha et al.	Case report	1	Bihar	30	Male	[32]
Ghanem et al.	Case report	1	Syria	26	Female	[33]
Chandra et al.	Case report	1	India	12	Male	[34]
Avcu et al.	Case report	1	Turkey	48	Male	[35]
Aydin et al.	Case report	1	Turkey	32	Female	[36]
Oksuz et al.	Case report	1	Turkey	32	Male	[37]
Bartın et al.	Case report	1	Turkey	32	Female	[38]
Perez et al.	Case report	1	Spain	64	Male	[39]

female predilection (59%). The age of patients was distributed between 5 and 70 years old, with a mean of 38.33 years (Table 3). The history of contact with animals was positive in 14.3% of the affected cases (Table 4). The most commonly presented symptom was mass (79.5%). Furthermore, 4% of the cases experienced hoarseness (Table 3). Serologic testing was conducted in 10 cases (20.75%), with a positive result in 18.75% of them (Table 4). The most commonly used modality of assessment was ultrasound (US) (77.5%), followed by Technetium-99 (27%). Surgery was the treatment of choice (96%). Total thyroidectomy (32.6%) and left hemithyroidectomy (16%) were the main surgical approaches in

the remaining cases, and cystectomy (12%) was the major technique for cyst removal. Conservative management was performed in 1 case (2%). One case (2%) underwent percutaneous intervention with the PAIR technique. Among cases with follow-up, the duration ranged mostly between 1 month and 1 year. Albendazole was administered in 51% of the cases (Table 5). The total recurrence rate was 0%, with only one case (2%) managed solely with conservative treatment (Table 5). Importantly, there were no recorded mortality rates pre- and post-intervention

**Table 2:** The distribution of the reported cases among countries.

Country	No. of cases	Percentage %
Turkey	14	36%
Iran	4	10.2%
India	3	7.7%
Spain	2	5.1%
Romania	2	5.1%
China	1	2.6%
Kurdistan	1	2.6%
Morocco	1	2.6%
Austria	1	2.6%
Libyan	1	2.6%
Italy	1	2.6%
Pakistan	1	2.6%
Tunisia	1	2.6%
Bihar	1	2.6%
Syria	1	2.6%
South Africa	1	2.6%
France	1	2.6%
Saudi Arabia	1	2.6%
NA	1	2.6%
Total	39	100 %

#### 4. Discussion

Hydatid disease has been known as a parasitic illness since the time of Hippocrates, and it continues to be prevalent in several locations, though mostly in regions like Eastern Europe, South Africa, the Middle East, South America, Australia, and the Mediterranean region, where cattle and sheep rearing is common [20]. This illness is especially prevalent in countries with a significant number of farming areas. However, it is currently regarded as a severe worldwide health issue as a result of increased immigration and travel. Hydatidosis was previously thought to be caused merely by the larval stage of *Echinococcus granulosus*. Still, it has recently been reported that a mixture of five species with ten distinct genotypes (G1-G10), including two bovid strains (G3/G5), two pig strains (G7 and G9), two sheep strains (G1 and G2), two Cervidae strains (G8 and G10), a horse strain (G4), and a camel strain (G6), can cause this disease. The five primary species are *E. oligarthrus* (G5), *E. equinus* (G4), *E. granulosus sensu stricto* (G1-G3), *E. canadensis* (G6-G10), and *E. felidis*. Among these species, *E. granulosus sensu stricto*, *E. granulosus sensu lato*, and *E. canadensis* are more frequent in humans [40].

Even in many highly endemic nations for this parasite, the thyroid localization of HC remains rare. As a result, the total prevalence of primary thyroid echinococcosis is estimated to be between 0.1 and 0.6. The first case of thyroid involvement was described by Reddy and M. Tangavelu in 1946 [3, 25]. There is some clarity on the pathogenesis routes.

The oncosphere larvae enter the systemic circulation after either skipping or making their way through the hepatic circulation to get to the thyroid gland (primary or secondary hydatid cysts). Because the gland's arteries are so tiny, even though it is an organ with substantial blood flow, hydatid cysts are uncommon

**Table 3:** The baseline characteristics of the patients.

Variables	Frequency/Percentage
Age	
min-max (average)	5-70(38.33)
Gender	
female	29 (59%)
Male	19 (39%)
NA	1 (2%)
PMH	
Contact with animal	7 (14.3%)
CVA	1 (2%)
Negative	3 (6%)
N/A	38 (77.5%)
PSH	
N/A	46 (94%)
Operated of hydatid cyst	2 (4%)
Plastic surgery for burned scar	1 (2%)
Presentation	
Mass	39 (79.5%)
Mass + dysphagia	1 (2%)
Dysphonia	1 (2%)
Dyspnea	1 (2%)
Pain in neck	1 (2%)
Hoarseness	2 (4%)
Stridor	1 (2%)
Anemia	1 (2%)
Mass+ dyspnea+ dysphagia	1 (2%)
Mass + hoarseness	1 (2%)
Examination Grade	
G1	27 (55%)
G2-3	1 (2%)
NA	2 (43%)
Consistency	
Firm	9 (18.75%)
Hard	1 (2%)
soft	11 (22.4%)
N/A	28 (57%)
Tenderness	
Tender	2 (4%)
Non-tender	23 (47%)
N/A	24 (49%)

[3]. In this systematic review, an intensive review of all the studies of thyroid HCs was conducted. The results revealed that Turkey is the most susceptible country to the occurrence of thyroid hydatidosis, with most of the reported cases (36%) belonging to this country. Following Turkey, Iran, India, Spain, and Romania were among the countries to report a high incidence of this disease. A small percentage of affected people have involvement in other organs such as the bone, kidney, muscle, pancreas, heart, and brain, while up to two-thirds have liver involvement, and up to 25% have lung involvement. Nonetheless, head and neck hydatidosis is an uncommon occurrence, even in endemic locations [15, 35, 41].

The condition is usually asymptomatic and discovered incidentally; however, symptoms may appear depending on the location and size of the cysts, and the patient may present with pressure symptoms. Hydatid cysts are typically slow-growing neck mass, but they can develop over time. Furthermore,

**Table 4:** Ultrasound, fine needle aspiration, and Hydatid cyst hemagglutinin findings of the patients.

Variable	Frequency/Percentage
Thyroid Function test	
TSH	
Normal	33 (67.3%)
Increase	2 (4%)
N/A	14 (28.5%)
T3	
Normal	33 (67.3%)
Increase	1 (2%)
N/A	15 (30%)
T4	
Normal	33 (67.3%)
N/A	16 (32.6%)
Ultrasound of thyroid gland	
Performed	38 (77.5%)
N/A	11 (22.4%)
Size of cyst by U/S	
<20 mm	4 (8.3%)
20-31 mm	7 (14.5%)
31-41 mm	11 (22.9%)
41-50mm	5 (10.4%)
Hydatid cyst hemagglutinin	
Positive	9 (18.75%)
Negative	1 (2%)
N/A	38 (79.5%)
Thyroid lobe involvement	
Left Lobe	22 (45.8%)
Right Lobe	20 (41.6%)
Both Lobe	6 (12.5%)
TC-99	
N/A	36 (73%)
Cold nodule	11 (22.4%)
Space occupying lesion	1 (2%)
Photopia	1 (2%)
Organ's involvement	36 (73%)
Not involved	7 (14%)
Lung	6 (12%)
Others	6 (12%)
Fine needle aspiration	
Hydatid cyst	4 (8%)
Watery fluid	5 (10%)
Not performed	4 (8%)
Not diagnostic	3 (6%)
Benign	1 (2%)
Acute thyroiditis	1 (2%)
N/A	31 (63%)

primary hydatid cysts are often solitary cystic lesions that affect a single thyroid lobe; however, several cysts might be found [3, 20]. In this study, the primary symptom identified in 79.5% of cases was a mass, while hoarseness occurred in 4% of cases. This highlights the variety of symptoms associated with hydatid cysts, with mass being the predominant manifestation.

Thus, serologic approaches are particularly effective in detecting hydatidosis. Almost all current serologic tests, such as CFT (Complement fixation test), IHA (Indirect

**Table 5:** Surgical management, HPE, Post-op medication, Recurrence.

Variables	Frequency/Percentage
Surgery	
Total thyroidectomy	16 (32.6%)
Subtotal thyroidectomy	4 (8%)
Left hemi-thyroidectomy	8 (16%)
Right hemi-thyroidectomy	5 (10%)
Left lobectomy	4 (8%)
Right lobectomy	2 (4%)
Surgical exploration	2 (4%)
Cyst removal	6 (12%)
Another modality	
Refused surgery (medication)	1 (2%)
Percutaneous intervention	1 (2%)
With the PAIR technique	
Post HPE	
Hydatid cyst	49 (100%)
Post-op medication	
N/A	25 (51%)
Took medication	24 (49%)
Recurrence	
No-Recurrence	49 (100%)

hemagglutination), LA (latex agglutination), IEP (Immuno-ElectroPhoresis), CIEP (Counter Immunoelectrophoresis), and ELISA (Enzyme-linked ImmunoSorbent Assay), have been used to diagnose hydatidosis from the beginning until today, and recently, in addition to ELISA, the Dot-ELISA test (Dot Enzyme-linked Immuno-Sorbent Assay) has been added seriously to the serologic diagnosis of hydatid cyst [42]. No case of thyroid hormone deficiency associated with this location has been found in the literature [25]. In the present study, 18.75% of cases exhibited positive IHA tests, in contrast with 2% that tested negative.

US, computed tomography scans (CT), magnetic resonance imaging (MRI), scintigraphy, and FNAC results provide the basis of the diagnosis [43]. Nonetheless, the majority of cases are identified following surgery, and the most reliable method of diagnosis is still post-surgical pathological examination recorded by Jain et al, Bauchardt et. An US is usually necessary to define the nature of the cyst radiographically. The most common presentation is a thin-walled cystic mass, occasionally accompanied by a detached membrane (water lily sign) or daughter cysts (honeycomb or rosette-like cysts). These characteristics (honeycomb cyst, rosette-like, or water lily sign) point to a hydatid origin. US sensitivity is still low, though. Furthermore, peripheral arciform calcification is not specific, even if it strongly implies the diagnosis. With a CT scan, the location of the cyst and its connection to surrounding organs may be more precisely defined [25]. Regarding the risk of cyst rupture, there is debate concerning the use of FNAC when a hydatid cyst is expected. Following the FNAC of the hydatid cysts, a range of consequences, from moderate allergic responses to anaphylactic reactions, have been recorded. The most frequent side effects include the development of an abscess and allergy after cyst rupture [3]. In this study, 77.5% underwent US, revealing primarily cystic lesions between 31 and 41mm in

size (22.9%), with the left thyroid lobe most affected (45.8%), followed by the right lobe (41.6%) and both lobes (12.5%). Scintigraphy identified a cold nodule in 23% of cases.

The main treatment for thyroid hydatid cysts is surgery, similar to cysts in other body parts. The goal is to remove the entire cyst without breaking it open [44]. For small cysts or those in specific areas, only part of the thyroid may be removed. During surgery, special precautions are taken to prevent spillage and allergic reactions. While surgery removes the cyst, medication like albendazole can help kill remaining parasites and reduce the chance of recurrence. Noteworthy complications associated with this procedure encompass organ damage, abscess formation, and the development of secondary cysts. Importantly, the risk of anaphylaxis looms large if the cyst undergoes an inadvertent rupture [6, 20, 22]. In the present study, 32.6% of patients underwent total thyroidectomy, and 16% underwent left hemithyroidectomy. Two patients refused surgery, with one opting for percutaneous intervention using the PAIR technique, and the other choosing medication. No postoperative complications were observed, and half of the patients received postoperative medication.

## 5. Conclusion

thyroid HC is more common in subtropical regions. The major diagnostic modality for this disease is the US, and serological tests cannot be relied on alone. The definitive treatment is surgery, mainly through a total thyroidectomy. A history of HC increases the likelihood of recurrence, and extensive follow-up is required.

## Declarations

**Conflicts of interest:** The author(s) have no conflicts of interest to disclose.

**Ethical approval:** Not applicable, as systematic reviews do not require ethical approval.

**Patient consent (participation and publication):** Not applicable.

**Funding:** The present study received no financial support.

**Acknowledgments:** None to be declared.

**Authors' contributions:** FHK and BAA were a major contributor to the conception of the study, as well as to the literature search for related studies. SFA, AAQ, SMA, and AMA were involved in the literature review, the writing of the manuscript, and data analysis and interpretation. IYA, HOK, MBAA, and ROM Literature review, final approval of the manuscript, and processing of the tables. HMD, YAS, ASM, HOB, AJQ, and AMS were involved in the literature review, the design of the study, and the critical revision of the manuscript. BAA and FHK Confirmation of the authenticity of all the raw data. All authors approved the final version of the manuscript.

**Use of AI:** AI was not used in the drafting of the manuscript, the production of graphical elements, or the collection and analysis of data.

**Data availability statement:** Not applicable.

## References

- Sultana N, Shah W, Ullah S, Ali M, Basharat S. Primary hydatid cyst of the thyroid gland: a case report. *Ann. Clin. Pathol.* 2016;4(3):1070. doi:N/A
- Woolsey ID, Miller AL. *Echinococcus granulosus sensu lato and Echinococcus multilocularis: A review. Research in veterinary science.* 2021 Mar 1; 135:517-22. doi:10.1016/j.rvsc.2020.11.010
- Safarpour MM, Aminnia S, Dehghanian A, Borazjani R, Abbassi HR, Boland Parvaz S, Paydar S. Primary hydatid cyst of the thyroid glands: two case reports and a review of the literature. *Journal of Medical Case Reports.* 2023 Oct 4;17(1):417. doi:10.1186/s13256-023-04141-3
- Eshraghi M, Shahmoradi L, Ghoddoosi M, Sadati SJ. Diagnosis of primary hydatid cyst of thyroid gland: a case report. *Biomolecular concepts.* 2019 Jun 3;10(1):106-10. doi:10.1515/bmc-2019-0013
- Seimenis A. Overview of the epidemiological situation on echinococcosis in the Mediterranean region. *Acta tropica.* 2003 Feb 1;85(2):191-5. doi:10.1016/S0001-706X(02)00272-3
- Akbulut S, Demircan F, Sogutcu N. Hydatid cyst disease of the thyroid gland: report of two cases. *International surgery.* 2015 Apr 1;100(4):643-7. doi:10.9738/INTSURG-D-14-00124.1
- Jiang T, Guo Q, Ran B, Zhang R, Aji T, Shao Y. Hydatid cyst of the thyroid gland with tracheal fistula: a case report and review of the literature. *Experimental and Therapeutic Medicine.* 2019 Jul 1;18(1):573-9. doi:10.3892/etm.2019.7620
- Muhaldeen AS, Ahmed JO, Baba HO, Abdullah IY, Hassan HA, Najjar KA, et al. Kscien's List; A New Strategy to Discourage Predatory Journals and Publishers (Second Version). *Barw Medical Journal.* 2023;1(1):14. Available from: doi:10.58742/BMJ.V1I1.14
- Lada P, Lermite E, Hennekinne-Mucci S, Etienne S, Pessaux P, Arnaud JP. Primary hydatid cyst of the thyroid, an unusual localisation of hydatidosis. *Presse Medicale (Paris, France):* 1983). 2005;34(8):580-. doi:10.1016/s0755-4982(05)83982-x
- Rauhofer U, Prager G, Hörmann M, Auer H, Kaserer K, Niederle B. Cystic echinococcosis of the thyroid gland in children and adults. *Thyroid.* 2003;13(5):497-502. doi:10.1089/105072503322021179
- Cretu CM, Serpoi G, Cilievici SE. Thyroid cystic echinococcosis: case presentation and review of the literature. *Ultraschall in der Medizin-European Journal of Ultrasound.* 2008;29(S 1): PP\_15\_5. doi:10.1055/s-2008-1080009
- Sersar SI, Batouk AO. Echinococcosis, bilateral pulmonary complicated and non-complicated with bilateral thyroid gland. *Asian Cardiovascular & Thoracic Annals.* 2013;21(4):485. doi:10.1177/10218492312454668
- Zulfikaroglu B, Ozalp N, Keskek M, Koc M. Primary echinococcal cyst of the thyroid: report of a case. *Surgery today.* 2008; 38:833-5. doi:10.1007/s00595-007-3796-x
- Erkılıç S, Öz Saraç C, Koçer NE, Bayazıt YA. Hydatid cyst of the thyroid gland in a child. *International journal of pediatric otorhinolaryngology.* 2004;68(3):369-71. doi:10.1016/j.ijporl.2003.11.002
- Çapoğlu İ, Ünüvar NE, Erdoğan F, Yılmaz O, Caydere M. A hydatid cyst of the thyroid gland. *Journal of International Medical Research.* 2002;30(2):206-9. doi:10.1177/147323000203000216
- Ozaydin I, Ozaydin C, Oksuz S, Yildirim M. Primary echinococcus cyst of the thyroid: a case report. *Acta Medica Iranica.* 2011;262-4. doi:N/A
- Gökçe C, Patiroğlu T, Akşehirli S, Durak AC, Keleştimur F. Hydatid cyst in the thyroid gland diagnosed by fine-needle aspiration biopsy. *Thyroid.* 2003 Oct 1;13(10):987-9. doi:10.1089/105072503322511409
- Ghawil M, Ben Omar N, Shatani A, Belhaj S, Doggah M. Primary hydatid cyst of the thyroid gland in a Libyan child. *INHORMONE RESEARCH IN PAEDIATRICS* 2023 Sep 1 (Vol. 96, pp. 437-437). ALLSCHWILERSTRASSE 10, CH-4009 BASEL, SWITZERLAND: KARGER. doi:N/A
- Jain SK, Jamdade PT, Muneshwar SS, Ambulgekar VK, Panzade SM. Hydatid cyst of thyroid: an unusual cause of stridor. *Indian Journal of Otolaryngology and Head and Neck Surgery.* 2005 Jan; 57:80-1. doi:10.1007/BF02907641
- Salih AM, Abdulla ZY, Mohammed DA, Jwamer VI, Ali PG, Hamasaheed AG, Shkur HH, Omer JK, Salih RQ, Mohammed SH, Muhaldeen AS. Hydatid cyst of thyroid gland, a rare case report with a literature review.

- International Journal of Surgery Case Reports. 2020 Jan 1; 67:267-70. [doi:10.1016/j.ijscr.2020.02.019](https://doi.org/10.1016/j.ijscr.2020.02.019)
21. Hoysal DR, Kulkarni S. Isolated primary hydatid disease of thyroid presenting as a solitary nodule: A rare case report. Indian Journal of Case Reports. 2019 Feb 26;79-81. [doi:N/A](https://doi.org/10.1016/j.ijscr.2020.02.019)
  22. Azendour I, Boulaich M, Ayoubi A, Oujilal A, Essakalli L, Kzadri M. Primary hydatid cyst of the thyroid gland. International Journal of Otolaryngology. 2011 Jan 1;2011. [doi:10.1155/2011/713089](https://doi.org/10.1155/2011/713089)
  23. Rajabian R, TAVASSOLI M, GHIASSI T, SHAKIB I M. Hydatid cyst of the thyroid. Medical Journal of The Islamic Republic of Iran (MJIRI). 1991 Nov 10;5(3):165-6. [doi:N/A](https://doi.org/10.1016/j.ijscr.2020.02.019)
  24. Erbil Y, Barbaros U, Baspinar I, Deveci U, Kapran Y, Bozboru A, Aral F, Özarmagan S. Hydatid cyst of the thyroid gland: two case reports. Infectious Diseases in Clinical Practice. 2005 Nov 1;13(6):318-20. [doi:10.1097/01.idc.0000168480.11589.fb](https://doi.org/10.1097/01.idc.0000168480.11589.fb)
  25. Bouomrani S, Souissi O, Regaieg N, BenHamed M. Primary Hydatid Cyst of the Thyroid Gland Revealed by Primary Hypothyroidism. Journal of Infectious Disease & Travel Medicine. 2018;2(3):000121. [doi:10.23880/JIDTM-16000121](https://doi.org/10.23880/JIDTM-16000121)
  26. El Bousaadani A, El Mahdoufi R, Roubal M, Mahtar M. Thyroid hydatid cyst: an unusual site. [doi:10.1016/j.anorl.2015.11.005](https://doi.org/10.1016/j.anorl.2015.11.005)
  27. Yilmaz M, Akbulut S, Sogutlu G, Arabaci E, Kayaalp C. Hydatid cyst of the thyroid gland: report of three cases. Surgery today. 2013 Aug; 43:937-41. [doi:10.1007/s00595-012-0269-7](https://doi.org/10.1007/s00595-012-0269-7)
  28. Eken H, Isik A, Balci G, Firat D, Cimen O, Soyuturk M. A rare case of isolated cystic hydatid of thyroid gland. Medicine. 2016 Mar;95(10). [doi:10.1097/MD.0000000000002929](https://doi.org/10.1097/MD.0000000000002929)
  29. Çıkmış AS, Pişkin T, Dirican A, Mecit E, Kahraman L, Olmez A, Kırımhoğlu V. Hydatid cyst in thyroid gland: a case report. Journal of Inonu University Medical Faculty. 2010 Jul 28;14(3):185-7. [doi:N/A](https://doi.org/10.1016/j.ijscr.2020.02.019)
  30. Bastanagh MH, Fatourehchi V, Rajabian R. Hydatid cyst presenting as a thyroid nodule: report of three cases. Acta Medica Iranica. 1995;31-4. [doi:N/A](https://doi.org/10.1016/j.ijscr.2020.02.019)
  31. Danilă R, Ionescu L, Livadariu R, Vulpoi C, Ciobanu D, Ungureanu MC. Primary hydatid cyst of the thyroid. Acta Endocrinol. (Buc.). 2015;11(4):529. [doi:10.4183/aeb.2015.529](https://doi.org/10.4183/aeb.2015.529)
  32. Saha A, Paul UK, Kumar K. Diagnosis of primary hydatid cyst in thyroid by fine needle aspiration cytology. Journal of Cytology. 2007 Jul 1;24(3):137-9. [doi: 10.4103/0970-9371.41904](https://doi.org/10.4103/0970-9371.41904)
  33. Ghanem M, Al Kazzaz MZ, Soliman A. Hydatid cyst in the neck, an unusual localization of the disease: a case report. International Journal of Surgery Case Reports. 2021 Aug 1; 85:106274. [doi:10.1016/j.ijscr.2021.106274](https://doi.org/10.1016/j.ijscr.2021.106274)
  34. Chandra T, Prakash A. A case of hydatid cyst of thyroid. British Journal of Surgery. 1965 Mar;52(3):235-7. [doi:10.1002/bjs.1800520324](https://doi.org/10.1002/bjs.1800520324)
  35. Avcu S, Ünal Ö, Kotan Ç, Öztürk M, Özen Ö. Submandibular and thyroid gland involvement of hydatid cysts: a very rare association with percutaneous treatment. Diagnostic and Interventional Radiology. 2010 Sep 1;16(3):251. [doi:10.4261/1305-3825.DIR.1967-08.2](https://doi.org/10.4261/1305-3825.DIR.1967-08.2)
  36. Aydın S, Tek C, Dilek Gokharman F, Fatihoglu E, Nercis Kosar P. Isolated hydatid cyst of thyroid: An unusual case. Ultrasound. 2018 Nov;26(4):251-3. [doi:10.1177/1742271X18770926](https://doi.org/10.1177/1742271X18770926)
  37. Oksuz S, Pektas E, Yavuz M, Aksungur N, Cayir Y, Akcay MN. An unusual cause of hoarseness: Hydatid cyst of the thyroid. Trop Biomed. 2013 Dec 1;30(4):642-4. [doi:N/A](https://doi.org/10.1016/j.ijscr.2020.02.019)
  38. Bartın MK, Yılmaz EM, Arslan H, Tekeli AE, Karataş S. A case of primary hydatid cyst in the thyroid gland. Turkish Journal of Surgery/Ulusal cerrahi dergisi. 2015;31(2):94. [doi:10.5152/UCD.2014.2668](https://doi.org/10.5152/UCD.2014.2668)
  39. Pérez PJ, Felmer EO, Carrasco EC, Gabrielli NM, Torrijos CC, Bastias NJ. Thyroid hydatid cyst: report of one case. Revista Medica de Chile. 2008 Jul 1;136(7):896-9. [doi:s0034-98872008000700012](https://doi.org/10.30034-98872008000700012)
  40. Akpınar I, Tekeli S, Sen T, Sen N, Basar N, Cagli KE, et al. Extremely rare cardiac involvement: recurrent pericardial hydatid cyst. Internal Medicine. 2012;51(4):391-3. [doi.org/10.2169/internalmedicine.51.6370](https://doi.org/10.2169/internalmedicine.51.6370)
  41. Maleki F, Akhlaghi L, Tabatabaie F. Evaluation of Hydatid Cyst Antigen for Serological Diagnosis. Medical Journal of the Islamic Republic of Iran. 2023;37. [doi:10.47176%2Fmjiri.37.87](https://doi.org/10.47176%2Fmjiri.37.87)
  42. Baba, H. O., Salih, A. M., Abdullah, H. O., Hassan, H. A., Ali, R. K., Kakamad, F. H., Salih, R. Q., & Mohammed, S. H. (2022). Primary hydatid cyst of the posterior neck; a case report with literature review. International Journal of Surgery Open, 40, 100449. [doi:10.1016/j.ijso.2022.100449](https://doi.org/10.1016/j.ijso.2022.100449)
  43. Abdullah, Ari M., Rashid, Rezheen J., Tahir, Soran H., Fattah, Fattah H., Hama, Jihad Ibrahim, Abdullah, Hiwa O., et al. Diagnosis of a pulmonary hydatid cyst by fine needle aspiration: a case report with literature review. Annals of Medicine & Surgery 86(1): p 552-555, January 2024. [doi:10.1097/MS9.0000000000001526](https://doi.org/10.1097/MS9.0000000000001526)
  44. Muhedin, S. S., Kakamad, F. H., Tahir, S. H., Baba, H. O., Salih, A. M., Qaradakh, A. J., et al. Hydatid cyst in the neck mimicking lymphangioma; a case report with a brief literature review. Otolaryngology Case Reports. 2022; 25: 100476. [doi:10.1016/j.xocr.2022.100476](https://doi.org/10.1016/j.xocr.2022.100476)