

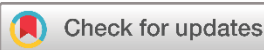Case Report

Tick Infestation on the Scalp Leading to Misguided Medical Consultation: A Case Report

Ronak Saeed Ahmed^{1,2}, Azad Star Hattam¹, Hiwa O. Abdullah^{1*}, Bilal A. Mohammed¹, Karzan M. Hasan¹, Honar Othman Kareem¹, Sasan M. Ahmed³, Hemin S. Mohammed¹, Shvan Omar Siddiq^{2,4}, Fahmi H. Kakamad⁵

1. Smart Health Tower, Madam Mitterrand Street, Sulaymaniyah, Kurdistan, Iraq
2. Shahid Nabaz Dermatology Teaching Center for Treatment of Skin Diseases, Sulaimani Directorate of Health, Sulaymaniyah, Kurdistan, Iraq
3. Kscien Organization for Scientific Research (Middle East office), Hamid Str, Azadi Mall, Sulaymaniyah, Kurdistan, Iraq
4. Kurdistan Board of Medical Specialties, Runaki Street, Erbil, Kurdistan, Iraq
5. College of Medicine, University of Sulaimani, Madam Mitterrand Street, Sulaymaniyah, Kurdistan, Iraq

* **Corresponding author:** hiewaom96@gmail.com (H.O. Abdullah). Mukryian Qtr 71, house number 57, Zip code: 46001, Sulaymaniyah, Kurdistan, Iraq



Keywords:

Tick bite
Tick infestation
Ixodes species
Severe headaches
Vector-borne diseases

Received: February 15, 2024
Revised: March 1, 2024
Accepted: March 20, 2024
First Published: March 28, 2024

Copyright: © 2024 Ahmed et al. This is an open access article distributed under the terms of the Creative Commons Attribution License (<https://creativecommons.org/licenses/by/4.0/>), which permits unrestricted use, distribution, and reproduction in any medium, provided the original author and source are credited.

Citation: Ahmed RS, Hattam AS, Abdulah HO, Mohammed BA, Hasan KM, Kareem HO et al. Tick Infestation on the Scalp Leading to Misguided Medical Consultation: A Case Report. Barw Medical Journal. 2024;2(2):68-71. <https://doi.org/10.58742/5dkgfp23>

Abstract

Introduction

Ticks frequently target wild, hairy mammals and can cause diverse complications when biting humans. This report highlights a case of scalp tick infestation in a child, leading to seeking unrelated medical consultation.

Case presentation

A 7-year-old female presented with a severe headache and neck stiffness for two days. The parents brought their child to a neurology clinic. Then, the patient was referred to a dermatology clinic due to a scalp tick infestation. The patient suffered from severe pain and irritability, making it difficult to tolerate any touch of the scalp. Physical examination revealed a few bleeding points, with a single grey tick (*Ixodes* species) firmly attached to the scalp. It was gently removed using blunt forceps and after 10 days of follow-up, there were no signs of scalp rash, fever, or lymphadenopathy.

Conclusion

Tick bites on the scalp can present with severe headaches and neck stiffness that may be disguised as other neurological conditions and cause seeking non-related medical consultation.

1. Introduction

Ticks, arachnid ectoparasites belonging to the families Ixodidae and Argasidae, serve as vectors for various infectious diseases. The Ixodidae family is characterized by a rigid and sclerotized

dorsal plate, known as hard ticks. Conversely, the Argasidae family lacks a rigid dorsal plate and is known as soft ticks [1,2]. Ticks are equipped with specialized mouthparts containing sharpened chelicerae, which can penetrate the host's skin during

feeding. The feeding process involves the formation of a blood pool, facilitating optimal nutrition uptake. They frequently target wild, hairy mammals and can cause diverse complications when biting humans, including skin granulomas, erythema chronicum-like lesions, and skin abscess formation. Moreover, ticks secrete saliva containing anti-coagulants and anti-inflammatory proteins, posing a risk of transmitting pathogenic diseases like Crimean-Congo hemorrhagic fever, Lyme disease, and tularemia [1,3,4]. Notably, the emerging concept of scalp eschar and neck lymphadenopathy (SENLAT) after tick bite enhances understanding of tick-related health issues. The SENLAT is characterized by a tick bite on the scalp, followed by the development of an eschar at the bite site and neck lymphadenopathy. Common accompanying symptoms include fever, myalgia, neck pain, and headaches [4]. Tick bites, beyond causing SENLAT, may lead to various clinical manifestations like local or secondary infection at the bite site, foreign body granuloma due to retained mouthparts, local contact/irritant allergic dermatitis, ascending paralysis, and even anaphylaxis [3]. This report highlights a case of scalp tick infestation in a child, leading to seeking unrelated medical consultation. Referenced studies have been checked to prevent citing non-peer-reviewed data [5].

2. Case Presentation

2.1. Patient information

A 7-year-old female presented with a severe headache and neck stiffness for two days. The parents brought their child to a neurology clinic. After a physical examination, the patient was referred to the dermatology clinic due to a scalp tick bite.

2.2. Clinical findings

The patient suffered from severe pain and irritability, making it difficult to tolerate any touch of the scalp. Physical examination revealed a few bleeding points, with a single grey tick (*Ixodes* species) firmly attached to the scalp (Figure 1). The case had a history of contact with a cow one week prior

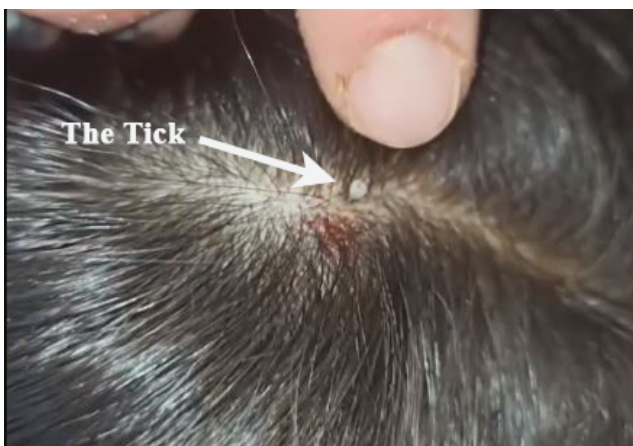

Figure 1: The infested tick on the patient's scalp.

2.4. Therapeutic intervention

The tick was gently removed using blunt forceps, ensuring no residual parts were left behind (Figure 2). The patient used Fucidin Ointment twice daily for one week.

2.4. Follow-up

After 10 days of follow-up, there were no signs of scalp rash, fever, or lymphadenopathy.




Figure 2: The live tick after removal from the patient's scalp

4. Discussion

Ticks are obligatory blood-sucking ectoparasites presenting on mammals, birds, amphibians, and reptiles. Their bites possess sufficient strength to pierce the skin of both animals and humans, potentially transmitting various infectious agents such as viruses, bacteria, and protozoa. Only a couple of species, Argasidae (soft ticks) and Ixodidae (hard ticks) are recognized for directly facilitating the transmission of pathogens to humans [1]. Hard ticks are more prevalent and pose a higher risk of disease transmission with the more challenging removal procedure [6,7]. Environmental factors influencing the development and distribution of ticks encompass favorable conditions for reproduction, spanning regions with diverse climates, high humidity, and the presence of livestock [1]. The duration of tick attachment varies from 1 to 10 days, with symptoms emerging between 1 and 14 days after the presumed tick bite [4]. The symptoms in the present case emerged after 5 days of having contact with a cow. She was complaining of severe headaches and neck stiffness for two days before seeking a medical consultation.

After a tick bite, various side effects may ensue and the tick's saliva can potentially lead to secondary infections by transmitting pathogens like *Staphylococcus aureus* and *Streptococcus* species, resulting in ecthyma, cellulitis, headache, vomiting, fever, and other complications [3]. Among these complications, our case had none except for severe headache, which was not correlated with infection.

Tick paralysis, a potentially dangerous outcome of a tick bite, is primarily characterized by severe and ascending paralysis. Ixodid ticks are more commonly associated with tick paralysis compared to Argasid ticks. The phenomenon is attributed to a specific protein injected into the host's blood during the blood-sucking process. *Ixodes holocyclus* secretes a toxin called holocyclotoxin, which induces hypertension. Additionally,

certain tick species release neurotoxins that diminish the action potential of motor neurons or impede acetylcholine neurotransmitter activity [8,9].

The SENLAT is another complication characterized as a non-pathogen-specific reaction to the bites of Dermacentor ticks [4,10]. The preference for ticks to bite children's or women's scalps is attributed to the parasite's affinity for hairy hosts. Diagnosis of SENLAT can be delayed due to the bite lesion being typically concealed by hair, and symptoms are often nonspecific. In a case reported by Barlozzari et al., the tick had been feeding for 10 days before its removal from the patient's scalp. The syndrome incubation period is between 1 to 55 days after a tick bite, usually between 5 and 10 days [11]. In the current case, assuming a 7-day tick bite, no complications such as SENLAT were encountered. This could be attributed to a different species, as in our case, the tick closely resembled Ixodes Ricinus.

However, tick infestation in humans is commonly reported to be caused by direct contact with domestic animals, as in the current case. Mohammed et al. reported a rare case of conjunctival tick attachment in an infant. The authors reported that the patient had no direct contact with domestic animals. The tick may have been transmitted from the parents, who lived in a rural area and owned livestock [1].

Yun et al., in their analysis of 31 reported cases of tick infestation, observed a higher prevalence of the condition in individuals aged 51 years and older compared to younger age groups [12]. Regarding the preferred site of infestation, the body trunk was the most frequently affected area, followed by the head and neck. Comparable to the current case, Chang et al. reported a tick infestation on the scalp of a 4-year-old child. However, in contrast to the present case, the child complained only of having an asymptomatic mass [7].

Given the elevated risk of disease transmission beyond 24 hours of tick attachment, prompt removal is imperative. Various chemical substances, including ether, iodine, lindane shampoo, and deodorized kerosene, have been suggested for tick detachment. However, these substances may induce irritation and prompt the tick to release infectious saliva. The most effective method involves mechanical intervention using blunt, medium-tip angled forceps. This approach is quick, simple, and deemed safe for tick removal [1,13]. The present case was managed using the latter technique. Systemic antimicrobial prophylaxis was not administered, as it is not recommended [13]. After 10 days of follow-up, the case had no signs of scalp rash, fever, or lymphadenopathy.

5. Conclusion

Tick bites on the scalp can present with severe headaches and neck stiffness that may be disguised as other neurological conditions and cause seeking non-related medical consultation.

Declarations

Conflicts of interest: The author(s) have no conflicts of interest to disclose.

Ethical approval: Not applicable.

Patient consent (participation and publication): Written informed consent was obtained from the parent for participation in the present study and the publication of the present case report and any accompanying images.

Funding: The present study received no financial support.

Acknowledgments: None to be declared.

Authors' contributions: RSA was a major contributor to the conception of the study, as well as to the literature search for related studies. ASH, HOA, and SOS were involved in the literature review, the writing of the manuscript, and data analysis and interpretation. KMH and HOK Literature review, final approval of the manuscript, and processing of the figures. SMA, HSM, and HHKA were involved in the literature review, the design of the study, and the critical revision of the manuscript. RSA and HOA Confirmation of the authenticity of all the raw data. All authors approved the final version of the manuscript.

Use of AI: AI was not used in the drafting of the manuscript, the production of graphical elements, or the collection and analysis of data.

Data availability statement: Not applicable.

References

- Mohammed RF, Abdulla BA, Mohammed SH, Salih RQ, Abdullah HO, Salih AM, et al. Conjunctival attachment of a live tick (Ixodes species) in an infant: a rare case report with literature review. *IJS Short Reports*. 2022;7(4): e61. [doi:10.1097/SR9.0000000000000061](https://doi.org/10.1097/SR9.0000000000000061)
- Dantas-Torres F, Chomel BB, Otranto D. Ticks and tick-borne diseases: a One Health perspective. *Trends in parasitology*. 2012;28(10):437-46. [doi:10.1016/j.pt.2012.07.003](https://doi.org/10.1016/j.pt.2012.07.003)
- Dana AN. Diagnosis and treatment of tick infestation and tick-borne diseases with cutaneous manifestations. *Dermatologic Therapy*. 2009;22(4):293-326. [doi:10.1111/j.1529-8019.2009.01244.x](https://doi.org/10.1111/j.1529-8019.2009.01244.x)
- Barbiero A, Manciuoli T, Spinicci M, Vellere I, Colao MG, Rossolini GM, et al. Scalp eschar and neck lymph adenopathy after a tick bite (SENLAT) in Tuscany, Italy (2015–2022). *Infection*. 2023;51(6):1847-54. [doi:10.1007/s15010-023-02079-8](https://doi.org/10.1007/s15010-023-02079-8)
- Muhaldeen AS, Ahmed JO, Baba HO, Abdullah IY, Hassan HA, Najar KA, et al: Kscien's List; A New Strategy to Discourage Predatory Journals and Publishers (Second Version). *Barw Medical Journal*. 2023; 1 (1): 1 3. [doi:10.58742/bmj.v1i1.14](https://doi.org/10.58742/bmj.v1i1.14)
- Anderson JF, Magnarelli LA. Biology of ticks. *Infectious disease clinics of North America*. 2008;22(2):195-215. [doi:10.1016/j.idc.2007.12.006](https://doi.org/10.1016/j.idc.2007.12.006)
- Chang SH, Park JH, Kwak JE, Joo M, Kim H, Chi JG, et al. A case of histologically diagnosed tick infestation on the scalp of a Korean child. *The Korean journal of parasitology*. 2006;44(2):157. [doi:10.3347/kjp.2006.44.2.157](https://doi.org/10.3347/kjp.2006.44.2.157)
- Edlow JA, McGillicuddy DC. Tick paralysis. *Infectious disease clinics of North America*. 2008;22(3):397-413. [doi:10.1016/j.idc.2008.03.005](https://doi.org/10.1016/j.idc.2008.03.005)
- Spach DH, Liles WC, Campbell GL, Quick RE, Anderson Jr DE, Fritsche TR. Tick-borne diseases in the United States. *New England Journal of Medicine*. 1993;329(13):936-47. [doi:10.1056/NEJM199309233291308](https://doi.org/10.1056/NEJM199309233291308)
- Dubourg G, Socolovschi C, Del Giudice P, Fournier PE, Raoult D. Scalp eschar and neck lymphadenopathy after tick bite: an emerging syndrome with multiple causes. *European journal of clinical microbiology & infectious diseases*. 2014; 33:1449-56. [doi:10.1007/s10096-014-2090-2](https://doi.org/10.1007/s10096-014-2090-2)
- Barlozzari G, Romiti F, Zini M, Magliano A, De Liberato C, Corrias F, et al. Scalp eschar and neck lymphadenopathy by Rickettsia slovaca after

Dermacentor marginatus tick bite case report: multidisciplinary approach to a tick-borne disease. BMC Infectious Diseases. 2021;21(1):1-4. [doi:10.1186/s12879-021-05807-3](https://doi.org/10.1186/s12879-021-05807-3)

12. YUN SK, KO GB, CHON TH. Tick bite: report of a case and review of Korean cases. Korean Journal of Dermatology. 2001;891-5. *doi:N/A*
13. Celik E, Türkoğlu EB, Boz AA, Alagöz G. Conjunctival attachment of a tick: case report. In Seminars in Ophthalmology. 2014; 29 (4):186-188. [doi:10.3109/08820538.2013.807847](https://doi.org/10.3109/08820538.2013.807847)