

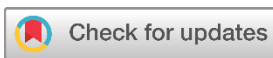Systematic Review

Non-Sacrococcygeal Pilonidal Sinus: A Systematic Review of a Growing Rare Disease

Ranj A. Hasan^{1*}, Fakher Abdullah², Bokan Talib Saeed¹

1. University clinic of Urology, Klinikum Herford, Germany
2. Kscien Organization for Scientific Research (Europe office), Verboomstraat 175b, 3082 jj Rotterdam, Netherlands

* Corresponding author: ranj.hasan@klinikum-herford.de (R.A. Hassan). Auf dem Dudel 53, 32049 Herford



Keywords:

Atypical
Pilonidal sinus
PNS
Non-Sacrococcygeal
Sacrococcygeal

Received: May 1, 2023

Revised: May 19, 2023

Accepted: June 2, 2023

Published: June 12, 2023

Copyright: © 2023 Hasan et al. This is an open access article distributed under the terms of the Creative Commons Attribution License (<https://creativecommons.org/licenses/by/4.0/>), which permits unrestricted use, distribution, and reproduction in any medium, provided the original author and source are credited.

Citation: Hasan RA, Abdullah F, Saeed BT. Non-Sacrococcygeal Pilonidal Sinus; A Rare but Growing Disease: A Systematic Review. Barw Medical Journal. 2023 Jun 12;1(2):49-53. <https://doi.org/10.58742/bmj.v1i2.39>

Abstract

Introduction

Clinical courses and management options for non-sacrococcygeal pilonidal sinus diseases have never been agreed on by the experts. The aim of this review is to collect, analyze, present, and discuss the management of pilonidal sinuses occurring in the body other than the sacrococcygeal regions.

Methods

PubMed/MEDLINE, Web of Science, Cochrane Library, and EMBASE and Google Scholar were explored for the related keywords. The inclusion criteria included those articles that mentioned at least the presentation and management of non-sacrococcygeal pilonidal sinuses. The collected data were re-analyzed (meta-data) and presented in the form of tables for a few variables and others were presented without analysis (review data).

Results

In 56 studies, 447 cases of non-sacrococcygeal pilonidal sinuses were found. About 367 (82%) were male. The mean age of presentation was 24.66 ranging from 8 to 70 years. The most prevalent site was the umbilicus (390 cases; 87.2%) followed by the mammary region (17 cases; 3.8%). The most prevalent clinical presentation of umbilical pilonidal sinus was swelling, discharge, and pain (83%). Only discharge was found in 20% and in 1.5% of the cases associated with bleeding. The most common management modality (187, 47.9%) was hair removal with regular dressing.

Conclusion

Non-sacrococcygeal pilonidal sinus is a rare variant of the disease. Among them, umbilical pilonidal sinus is the most prevalent one. Swelling, discomfort, and discharge are the usual presenting symptoms. Non-sacrococcygeal PNDs are managed by excision and primary suturing apart from umbilical PND which is usually treated by conservative measures.

1. Introduction

Pilonidal sinus disease (PND) is an inflammatory condition that originated from hair penetration into the epidermis. In this condition, a blind tract will be formed which is lined by granulation tissues [1]. The clinical signs are the same spectrum of signs and symptoms of inflammation including pain, hotness, erythema, and tenderness, sometimes it presents as an intermittent purulent discharge [2, 3]. Usually, it appears in the

sacrococcygeal region of those persons with prolonged sitting like the drivers [4]. Several techniques have been practiced as a management strategy of PND. These include removal of the hairs and cotton-like dirties in outpatient clinics and excision with or without flaps. General, regional, or local anesthesia has been used in the intervention [5]. Recently, non-operative management has been increasingly discussed in the literature [6]. Several non-sacrococcygeal PNDs have been reported in the literature including small case series and case reports [5, 7, 8].

This type of PNS is sometimes misdiagnosed as another disease [9]. Clinical courses and management options for non-sacrococcygeal PND have never been agreed on by the experts. The aim of this review is to collect, analyze, present, and discuss the management of PND occurring in the body other than the sacrococcygeal regions.

2. Methods

2.1. Study design

This study was a systematic review of the studies focusing on the treatment of Non-Sacrococcygeal Pilonidal Sinus. It was conducted in accordance with the PRISMA 2020 guidelines.

2.2. Data sources and search strategy

PubMed/MEDLINE, Web of Science, Cochrane Library, EMBASE and google scholar were explored for the following keywords: pilonidal sinus(es) of unusual area, non-sacrococcygeal pilonidal sinus(es), and atypical pilonidal sinus(es).

2.3. Eligibility criteria

The inclusion criteria included those articles that mentioned at least the presentation and management of non-sacrococcygeal PND.

2.4. Study selection and data items

The collected data were re-analyzed (meta-data) and presented in the form of tables for a few variables and others were presented without analysis (review data). Those articles that have been published by predatory journals were excluded. Predatory journals and publishers have been defined according to Kscien's list [10].

2.5. Data analysis and synthesis

The Statistical Package for the Social Sciences software (version 25) was utilized to analyze the data qualitatively (descriptive analysis). The data were represented as frequencies, and percentages.

3. Results

The search found 245 items. From these studies, 63 articles were excluded by the titles as they were duplicate or unrelated papers. Another 95 articles were excluded from the study as they did not meet the inclusion criteria. Twenty-nine articles were excluded because of missing data, and 2 articles were excluded because of being published by predatory journals (figure 1). In 56 studies, 447 cases of non-sacrococcygeal PND were found. About 367 (82%) were male. The mean age of presentation was 24.66 ranging from 8 to 70 years. The most prevalent non-sacrococcygeal site of PND was the umbilicus (390 cases; 87.2%) followed by the mammary region (17 cases; 3.8%). Table 1 reveals the frequency and sites of non-sacrococcygeal PND.

The most prevalent clinical presentation of umbilical PND was swelling, discharge, and pain (83%). Only discharge was found in 20% and in 1.5% of the cases associated with bleeding. The most common management modality (187, 47.9%) was hair removal with regular dressing. This was done with or without anesthesia. Otherwise, operative umbilectomy which was performed under general anesthesia had a 2% recurrent rate. Interdigital and hand PNDs presented with a discharging sinus in (80%) of the cases. This is usually managed by excision under general anesthesia. Scalp PNDs presented with scalp nodules. Craniotomy was indicated in one case, the remaining patients were managed by excision and direct closure. Patients with intermammary PNDs had pain and discharge and were managed by excision, followed by primary repair. Discharge and pain on defecation were the hallmarks of perineal PND. It was managed with surgical drainage and left open for secondary healing. Abscess formation was found in penile PND, it was managed by excision and direct closure. Clitoris PND in female patients presented with pain and swelling and pain. Treatment included excision and direct closure. Swelling and discharge were also found in prepuce PND. They were managed with excision and direct closure.

4. Discussion

Several risk factors have been proposed for umbilical PND, these included male gender, young age, hairiness, and poor hygiene. The presentations of umbilical PND include pain, purulent discharge, umbilical mass, and bloody discharge [10]. The current review confirmed these findings.

Non-operative management has a minimal role in sacrococcygeal PND (sPND) and it needs excision with either primary closure or leaving the wound for secondary healing [1]. However, PND involving the umbilical region can be fruitfully managed by conservative measures including hair removal and daily dressings [3-5,8-16]. This may not need even local anesthesia [3-5,8-16].

Recurrence is common (15%) in sPND, while non-sacrococcygeal PND (including umbilical regions) has a lower rate of recurrence 2% [10,20,30]. There have been 12 recorded recurring occurrences of umbilical PNS. Two cases underwent an operation, whereas other cases were managed conservatively [8,9,23]. This shows that the rate of recurrence for conservative and surgical treatments may not be different significantly, but some researchers vehemently disagree with this conclusion [11]. To resolve this debate, more research is required. Other diseases including Sister Joseph nodule, endometriosis, umbilical hernia, urachal cyst, pyogenic granuloma, and the epidermoid cyst should not be disregarded as the differential diagnosis when dealing with umbilical PND. In this situation, preoperative imaging might be useful [8].

Another term for PND of the hand is Barber's disease [6]. It affects hair stylists, sheep shearers, dog groomers, and cow milkers in addition to drivers, who frequently get sacrococcygeal PNS (6). It is more frequently reported by male hair stylists [6]. Males are more likely to get Barber's illness, which may be related to the higher prevalence of feminine

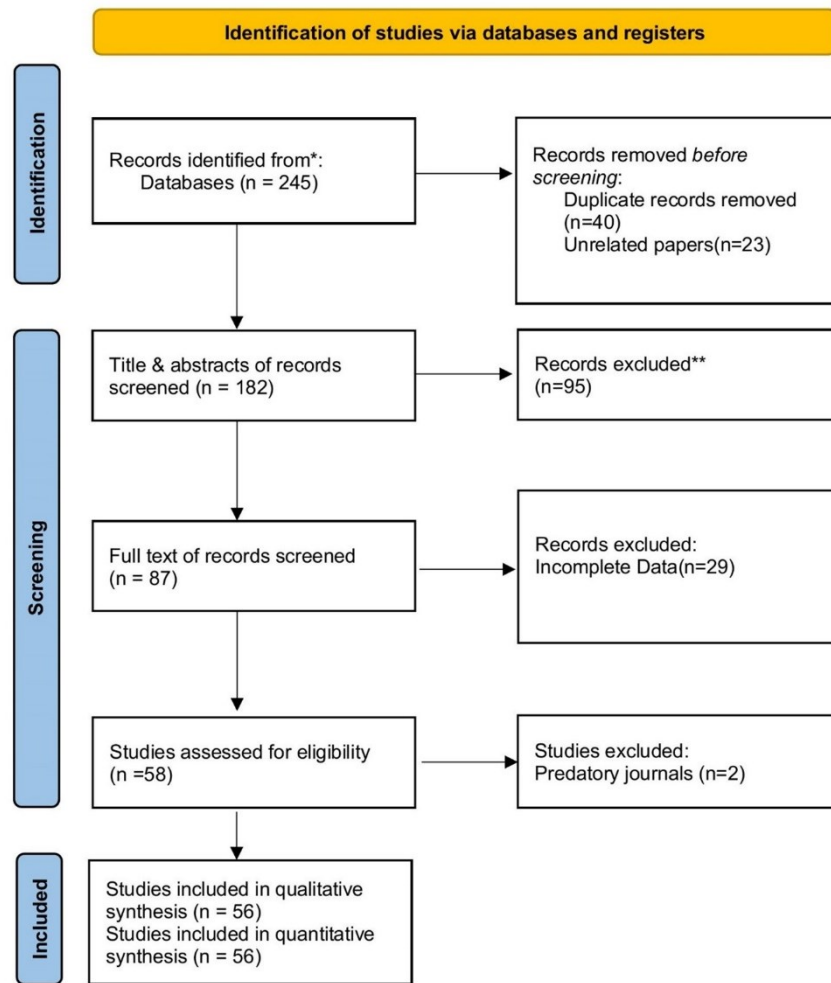


Figure 1. Study selection PRISMA flow chart.

obsessive personalities over the removal of interdigital webs or the fact that most barbers are men.

Teenagers and young children, ranging in age from 1 to 20 years, with an average of 10 years old, are known to have scalp PND. This distinguishes scalp PND from other PND forms that often affect elderly persons (average 23 years old). The most frequent form of therapy, excision under local anesthetic, has never been associated with recurrences [2,24,25]. According to Borges et al., a 20-year-old guy with cerebral extension had a scalp PND that required a craniotomy under general anesthesia. This may prompt medical professionals to look at scalp PND prior to intervention to look for an intracranial extension. The initial test may be a straightforward anteroposterior skull x-ray, followed by a brain computed tomography [2].

PND occurring near the anal canal is called perineal PNS, it usually presents with pain and discomfort during straining. It needs opening, drainage, and leaving for secondary healing as the area is already contaminated. Perianal PND usually occurs in older patients (older than 34 years) [30]. Excision is the most common treatment method under regional anesthesia [1,7,8]. According to Doll et al, a 61-year-old woman who had

intermittent anal discomfort caused by endoanal PND for ten years was healed by opening the cavity and allowing for secondary intention healing [29]. Intermammary PND commonly presented with discharge and pain. It was managed by wide local excision and primary repair.

Abscess of the penis could be penile PND, excision with primary suturing is the management strategy of choice. PND involving the clitoris presents with discomfort and swelling. Resection and primary closure are the treatment of choice. Prepuce PND also needs excision and primary suturing [7,33-35].

5. Conclusion

As predicted, non-sacrococcygeal PND is a rare variant of the disease. Among them, Umbilical PND is the most prevalent one. Swelling, discomfort, and discharge are the usual presenting symptoms. Non-sacrococcygeal PNDs are managed by excision and primary suturing apart from umbilical PND which is usually treated by conservative measures.

Table 1: The frequency and sites of non-sacroccygeal PND.

Sites	Number of the cases	Percentage %	Reference
Umbilicus	390	87.2	[3,5,11-22]
Intermammary and breast	17	3.8	[23-28]
Hand	14	3.1	[7,8,29-35]
Inguinal region	10	2.2	[36-45]
Face	7	1.6	[46-53]
Scalp	4	0.9	[2,54-56]
Perianal	3	0.7	[1,57, 58]
Neck	2	0.4	[59,60]
Total	447		

Declarations

Conflicts of interest: The author(s) have no conflicts of interest to disclose.

Ethical approval: Not applicable, as systematic reviews do not require ethical approval.

Patient consent (participation and publication): Not applicable.

Funding: The present study received no financial support.

Acknowledgements: None to be declared.

Authors' contributions: RAH, BTS participated in data collection, performed the data analysis, participated in preparing the manuscript. FA designed the study, critically revised the manuscript, design of the study. RAH, BTS confirmed the authenticity of the data. All authors approved the final version of the manuscript.

Data availability statement: Not applicable.

References

- Salih AM, Kakamad FH. A case report of endoanal pilonidal sinus. *Journal of Case Reports and Images in Surgery*. 2016;2. [doi:10.5348/Z12-2016-24-CR-16](https://doi.org/10.5348/Z12-2016-24-CR-16)
- Borges G, Maciel Jr JA, Carelli EF, Alvarenga M, De Castro R et al. Pilonidal Cyst on the vault case report. *Arqneuropsiquiater*. 1999;57(2A):273-276. [doi:10.1590/s0004-282x1999000200017](https://doi.org/10.1590/s0004-282x1999000200017)
- Colapino ND. Umbilical pilonidal sinus. *Br J Surg*. 1977;64:494-495. [doi:10.1002/bjs.1800640712](https://doi.org/10.1002/bjs.1800640712)
- Faruq H, Faraj, Hiwa O, Baba, Abdulwahid M, Salih, Fahmi H, kakamad. Risk factors of pilonidal sinus disease in preparatory school students; a case control study. *Annals of Medicine and Surgery*. 2020;57:46-48. [doi:10.1016/j.amsu.2020.07.016](https://doi.org/10.1016/j.amsu.2020.07.016)
- Akkapulu N, Tanrikul Y. Umbilical Pilonidal Sinus: A Case Report. *J Med Cases*. 2011;2(6):272- 274. [doi:10.4021/jmc348w](https://doi.org/10.4021/jmc348w)
- Abdulwahid M, Salih, Fahmi H, Kakamad, Rawezh Q, Salih, Shvan H, Mohammed, Imad J, Habibullah, Zuhair D, Hammood, et al. Nonoperative management of pilonidal sinus disease: one more step toward the ideal management therapy—a randomized controlled trial. *Surgery*. 2018;164(1):66-70. [doi:10.1016/j.surg.2017.12.014](https://doi.org/10.1016/j.surg.2017.12.014)
- Efthimiadis C, Kosmidis C, Anthimidis G, Grigoriou M, Levva S, Psihidis PFG. Barber's hair sinus in a female hairdresser: uncommon manifestation of an occupational disease: a case report. *Cases Journal*. 2008;1(1):1. [doi:10.1186/1757-1626-1-214](https://doi.org/10.1186/1757-1626-1-214)
- Gul VO, Destek S, Etkin E, Ozer S, Ahioğlu S. Approach To Interdigital Pilonidal Sinus – Extended case report and literature summary. *Pilonidal Sinus Journal*. 2016;2(1):5-12. [doi:N/A](https://doi.org/10.58742/bmj.v1i2.39)
- Abdulwahid M, Salih a, F.H. Kakamad b,*, Goran M. rauf. Basal cell carcinoma mimicking pilonidal sinus: A case report with literature review. *International Journal of Surgery Case Reports*. 2016;28:121-123. [doi:10.1016/j.ijscr.2016.09.040](https://doi.org/10.1016/j.ijscr.2016.09.040)
- Aso S, Muhiyaldeen, Jaafar Omer Ahmed, Hiwa O, Baba, Ismael Y, Abdullah, Hemn Ali Hassan, Kayhan A, Najjar, et al. Kscien's list; a new strategy to discourage predatory journals and publishers (second version). *Barw Medical Journal*. 2023;1(1): 1-3. [doi:10.58742/bmj.v1i1.14](https://doi.org/10.58742/bmj.v1i1.14)
- Mustafa G, Akber G, Lodhi JK, Mutahir M, Malik A. Umbilical pilonidal sinus. *J Ayub Med Coll Abbottabad*. 2014;26(1). [doi: N/A](https://doi.org/10.58742/bmj.v1i1.14)
- Fazeli MS, Lebaschi AH, Adel MG, Kazemini AR. Evaluation of the Outcome of Complete Sinus Excision with Reconstruction of the Umbilicus in Patients with Umbilical Pilonidal Sinus. *World J Surg*. 2008;32:2305–2308. [doi:10.1007/s00268-008-9626-5](https://doi.org/10.1007/s00268-008-9626-5)
- Jayalakshmy P, Leelamma L, Mohammed BA. Umbilical pilonidal cyst presenting as umbilical sepsis. *International Journal of Advances in Medicine*. 2014; 8(3). [doi:10.18203/2349-3933.ijam20160205](https://doi.org/10.18203/2349-3933.ijam20160205)
- Eryilmaz R, Sahin M, Okan I, Alimoglu O, Somay A. Umbilical Pilonidal Sinus Disease: Predisposing Factors and Treatment. *World J Surg*. 2005;29:1158–1160. [doi:10.1007/s00268-005-7895-9](https://doi.org/10.1007/s00268-005-7895-9)
- Mathew M, Goel G. Umbilical pilonidal sinus mimicking umbilical adenoma. *The Internet Journal of Surgery*. 2008;2(1):1-3. [doi:N/A](https://doi.org/10.58742/bmj.v1i1.14)
- Gupta S, Sikora S, Singn M, Sha L. Pilonidal Disease of the Umbilicus - A Report of Two Cases. *Japanese Journal of Surgery*. 1990;20(5):590-592. [doi:10.1007/BF02471018](https://doi.org/10.1007/BF02471018)
- Al-Kadi AS. Umbilical Pilonidal Sinus. *International journal of health sciences*. 2014;8(3):307. [doi:10.12816/0023983](https://doi.org/10.12816/0023983)
- McClenathan JH. Umbilical pilonidal sinus. *Canadian Journal of Surgery*. 2000;43(3):225. [doi:N/A](https://doi.org/10.58742/bmj.v1i1.14)
- Kareem T. Outcomes of conservative treatment of 134 cases of umbilical pilonidal sinus. *World J Surg*. 2013;37(2):313-7. [doi:10.1007/s00268-012-1819-2](https://doi.org/10.1007/s00268-012-1819-2)
- Meher S, Mishra TS, Sasmal PK, Sharma R, Rout B. Umbilical Pilonidal Sinus: A Report of Two Cases and Recent Update of Literature. *Journal of Clinical and Diagnostic Research*. 2016;10(9):20-22. [doi:10.7860/JCDR/2016/20251.8569](https://doi.org/10.7860/JCDR/2016/20251.8569)
- Hazhir JSM, Shahvari M. Non-surgical treatment of umbilical pilonidal sinus in adolescent and adult cases. *Polish Journal of Surgery*. 2011;83(12):652-653. [doi:N/A](https://doi.org/10.58742/bmj.v1i1.14)
- Muhiyaldeen A. S., Baba H. O., Salih A. M., Fathalla B. L., Latif S., Hasan S. J., Mohammed R. O., et al. Non-operative management of umbilical pilonidal sinus: One more step towards ideal therapy. *International Wound Journal*. 2023;20(5):1-6. [doi:10.1111/iwj.14111](https://doi.org/10.1111/iwj.14111)
- Lahiri R, Mullen R, Ashton MA, Abbott NC, Pollock AM. Pilonidal abscess in the breast: a case report. *Journal of surgical case reports*. 2014;(6):2. [doi:10.1093/jscr/rju061](https://doi.org/10.1093/jscr/rju061)
- Yavalkar P, Shelke R. Intermammary Pilonidal Sinus: A Case Report. *Indian Journal of Medical Case Reports*. 2014;3(2):20-22. [doi:N/A](https://doi.org/10.58742/bmj.v1i1.14)
- Abdulwahid SM, Kakamad FH, Abdulqadr MH. Intermammary pilonidal sinus: A rare presentation. *International Journal of Case Reports and Images*. 2016;7(1):48-50. [doi:10.5348/ijcri-201610-CR-10597](https://doi.org/10.5348/ijcri-201610-CR-10597)
- Seerwan Hama Shareef, Tahir A, Hawrami, Abdulwahid M, Salih, Fahmi H, Kakamad, Hawbash M, Rahim, Hunar A, Hassan, et al. Intermammary pilonidal sinus: The first case series. *International Journal of Surgery Case Reports*. 2017; 41: 265-268. [doi:10.1016/j.ijscr.2017.10.021](https://doi.org/10.1016/j.ijscr.2017.10.021)
- Abdulwahid M, Salih, Fahmi H, Kakamad, Zuhair D, Hammood, Hiwa O, Baba, Imad J, Habibullah, Rawezh Q, Salih, et al. Pilonidal sinus of breast: A case report with literature review. *International Journal of Surgery Case Reports*. 2020; 66: 204-206. [doi:10.1016/j.ijscr.2019.11.057](https://doi.org/10.1016/j.ijscr.2019.11.057)
- Gannon MX, Crowson MC, Fielding JW. Periareolar pilonidal abscesses in a hairdresser. *British Medical Journal*. 1988;666(297):1641. [doi:10.1136/bmj.297.6664.1641-a](https://doi.org/10.1136/bmj.297.6664.1641-a)
- Grant P, Mahaffey J. Pilonidal sinus of the finger pulp. *The Journal of Hand Surgery: British & European*. 2001;26(5):490-491. [doi:10.1054/jhsb.2001.0580](https://doi.org/10.1054/jhsb.2001.0580)
- Ito A, Yoshida Y, Yamamoto O. Case of interdigital pilonidal sinus in a dog groomer. *The Journal of Dermatology*. 2013;40(12):1051-2. [doi:10.1111/1346-8138.12343](https://doi.org/10.1111/1346-8138.12343)
- Jawade KK, Jawade PG. Pilonidal sinus in palmar webspace of a male barber: a case report with review of literature. *International Surgery Journal*. 2016;3(1):382-5. [doi:10.18203/2349-2902.isj20160264](https://doi.org/10.18203/2349-2902.isj20160264)
- Vaiude P, Dhital M, Hancock K. A true pilonidal sinus in the hand of a sheep shearer. *Journal of surgical case reports*. 2011;12:6. [doi:10.1093/jscr/2011.12.6](https://doi.org/10.1093/jscr/2011.12.6)

33. Patel MR, Bassini L, Nashad R, Anselmo MT. Barber's interdigital pilonidal sinus of the hand: a foreign body hair granuloma. *The Journal of hand surgery*. 1990;15A(652):5. [doi:10.1016/s0363-5023\(09\)90031-4](https://doi.org/10.1016/s0363-5023(09)90031-4)
34. Uysal AC, Orbay H, Uraloglu M, Sensoz O, Hyakusoku H. A rare occupational disease of hair dressers: Interdigital pilonidal sinus. *Journal of Nippon Medical School*. 2007;74(5):364-366. [doi:10.1272/jnms.74.364](https://doi.org/10.1272/jnms.74.364)
35. Abdullah Ors, Birkan Kibar. Bilateral interdigital pilonidal sinus of the hand in amale hairdresser. *Joint disease and related surgery*. 2021;32(2):523-525. [doi:10.52312/jdrs.2021.263](https://doi.org/10.52312/jdrs.2021.263)
36. Limgam MK, Hayes M, Mackay C. Pilonidal sinus of penis. *British Journal of Urology*. 1996;78:657-8. [doi:10.1046/j.1464-410X.1996.21436.x](https://doi.org/10.1046/j.1464-410X.1996.21436.x)
37. Baker T, Barclay D, Ballard C. Pilonidal Cyst Involving the Clitoris: A Case Report. *Journal of Lower Genital Tract Disease*. 2008;12(2):127-9. [doi:10.1097/LGT.0b013e3181579306](https://doi.org/10.1097/LGT.0b013e3181579306)
38. Ritchi JD. Pilonidal Sinus of the Prepuce. *British Journal of Urology*. 1975;41:580. [doi:10.1111/j.1464-410x.1975.tb06267.x](https://doi.org/10.1111/j.1464-410x.1975.tb06267.x)
39. Shylashree Chikkamuniyappa, Jaime Furman, Rolf Sjuve Scott. Pilonidal Sinus of the Glans Penis Associated with Actinomyces. *The Scientific World Journal*. 2004; 4, 908-912. [doi:10.1100/tsw.2004.188](https://doi.org/10.1100/tsw.2004.188)
40. Luigi Cormio, Francesca Sanguedolce, Paolo Massenio, I Giuseppe Di Fino, Giuseppe Carrieri. Pilonidal Cyst of the Penis Mimicking Carcinoma. *Case Reports in Urology*. 2013;1:1-2. [doi:10.1155/2013/984757](https://doi.org/10.1155/2013/984757)
41. Hakan Ercil, Ergun Alma, Mehmet Eflatun Deniz, Umüt Unal, Alper Sozutek. Recurrent Pilonidal Sinus Cyst on Penis. *Archive of Iranian Medicine*. 2018; 21(3):131-133. [doi:10.1155/2018/131133](https://doi.org/10.1155/2018/131133)
42. C. Fisher, J. L. Peters, R. O'N. Witherow. *The Journal of Urology*. 1976;116:816-817. [doi:10.1016/S0022-5347\(17\)59028-X](https://doi.org/10.1016/S0022-5347(17)59028-X)
43. Hugh F. O'Kane, B. Duggan, C. Mulholland J. Crosbie. Pilonidal Sinus of the Penis. *The Scientific World Journal*. 2004; 4 (S1): 258-259. [doi:10.1100/tsw.2004.74](https://doi.org/10.1100/tsw.2004.74)
44. Zubair Al-Qassim, Kiran Reddy, Zeb Khan, Ippala Sreenath Reddy. Pilonidal sinus cyst of the penis: a rare manifestation of a common disease. *British Medical Journal*. 2013;1:1-2. [doi:10.1136/bcr-2013-009718](https://doi.org/10.1136/bcr-2013-009718)
45. Amrith Raj Rao, Mohit Sharma, Mabel Thyveetil, Omer MA Karim. Penis: An unusual site for pilonidal sinus. *International Urology and Nephrology*. 2006; 38:607-608. [doi:10.1007/s11255-005-4761-5](https://doi.org/10.1007/s11255-005-4761-5)
46. Sreedharan S, Kamath PM, Hegde MC, Subramaniam V, Lobo FD. Pilonidal sinus of nose—a diagnostic dilemma. *Journal de chirurgie*. 2010;6(3):343-7. [doi:10.1155/2010/343347](https://doi.org/10.1155/2010/343347)
47. Abdulwahid SM, Kakamad FH. Preauricular pilonidal sinus: The first reported case. *International Journal of Case Reports and Images*. 2016;7(3):162-164. [doi:10.5348/ijcri-201626-CR-10613](https://doi.org/10.5348/ijcri-201626-CR-10613)
48. Raghvi Anand, Priya Kanagamuthu. Hair in the Wrong Place: A Rare Case of Pilonidal Sinus in Preauricular Sinus Tract. *Indian Journal of Otolaryngology*. 2022; 28:258-61. [doi:10.1155/2022/258261](https://doi.org/10.1155/2022/258261)
49. Sebahattin Destek, I Vahit Onur Gul, 2 and Serkan Ahioğlu. Rare Type Cranial Postauricular Pilonidal Sinus: A Case Report and Brief Review of Literature. *Case Reports in Surgery*. 2017;1:1-4. [doi:10.1155/2017/5791972](https://doi.org/10.1155/2017/5791972)
50. Sercan Kucukkurt, Murat Ozle, Sharif Rzayev. Pilonidal sinus of the chin: mistreated as a dental fistula. *British Medical Journal Case Report*. 2016;1:1-4. [doi:10.1136/bcr-2015-213639](https://doi.org/10.1136/bcr-2015-213639)
51. Abdulwahid M. Salih, Fahmi H. Kakamad, Shvan H. Mohammed, A. Hussein Dahat, Tariq H. Lhun. Postauricular pilonidal sinus: a case report with literature review. *Pilonidal Sinus Journal*. 2015;3(1):28-31. [doi:10.1155/2015/2831](https://doi.org/10.1155/2015/2831)
52. Abdulwahid M. Salih, Shko H. Hassan, Marwan N. Hassan, Mariwan L. Fatah, Fahmi H. Kakamad, Bastoon Kh Salih, et al. Auricular pilonidal sinus; a rare case with a brief review of literature, *International Journal of Surgery Open*. 2022;43. [doi:10.1016/j.ijso.2022.100489](https://doi.org/10.1016/j.ijso.2022.100489)
53. Abdulwahid M. Salih, F.H. Kakamad, Imad J. Habibullah, Mustafa H. Abdulqadr. Submental pilonidal sinus - the first reported case. *Pilonidal Sinus Journal*. 2017; 3(1), 14 – 18. [doi:10.1155/2017/1418](https://doi.org/10.1155/2017/1418)
54. Salih AM, Kakamad FH. Scalp pilonidal sinus: A case report. *International Journal of Case Reports and Images*. 2016;7(3):175-177. [doi:10.5348/ijcri-201629-CR-10616](https://doi.org/10.5348/ijcri-201629-CR-10616)
55. Chiu MW, Abrishami P, Sadeghi P. Letter: pilonidal cyst of the scalp. *Dermatologic Surgery*. 2008;34(9):1294-1295. [doi:10.1007/s12247-008-9294-4](https://doi.org/10.1007/s12247-008-9294-4)
56. Nalbant OA, Nalbant E. Pilonidal Sinus of the Scalp: a Case Report and Review of the Literature. *Balkan Medical Journal*. 2011;28:445-7. [doi:10.5174/tutfd.2010.03495.4](https://doi.org/10.5174/tutfd.2010.03495.4)
57. Talimi C, Fracaro GB, Cezar A, Araújo F, dos Reis Lima DM, Westphalen AP. Endoanal pilonidal sinus: case report and literature review. *Journal of Coloproctology*. 2015;35(3):175-177. [doi:10.1016/j.jcol.2015.04.002](https://doi.org/10.1016/j.jcol.2015.04.002)
58. Doll D, Stauffer VK, Luedi MM. Intra-anal pilonidal sinus disease: a unique diagnosis possibly pointing to the occiput. *ANZ J Surg*. 2016; 86:622-625. [doi:10.1111/ans.13473](https://doi.org/10.1111/ans.13473)
59. Abdulwahid M. Salih, Fahmi H. Kakamad, Rawezh Q. Salih, Hiwa O. Baba, Shvan H. Mohammed, Kayhan A. Najjar et al. Pilonidal sinus of neck: A case report. *International Journal of Case Report and Images* 2018;9:1-4. [doi:10.58742/IJCR.2018.09.001](https://doi.org/10.58742/IJCR.2018.09.001)
60. Abdulwahid M. Salih, Fahmi H. Kakamad, Hunar A. Hassan, Goran M. Rauf, Imad J. Habibullah3 , Zuhair D. Hammood et al. Pilonidal sinus of neck; a case report with literature review. 2017.1:1-5. [doi:10.1155/2017/115](https://doi.org/10.1155/2017/115)